

# The Clinical Significance of Sinus Membrane Perforation During Augmentation of the Maxillary Sinus

*Leon Ardekian, DDS,\* Efrat Oved-Peleg, DMD,†  
Eli E. Mactei, DMD,‡ and Micha Peled, DMD, MD§*

**Purpose:** Augmentation of the maxillary sinus floor is a well-documented technique and is generally accepted as a pure implantology procedure to facilitate placement of dental implants in the posterior atrophic maxilla. The objective of this report was to evaluate the significance of the sinus membrane perforations on the incidence, complications, and success rate of this procedure.

**Patients and Methods:** Patients who received sinus floor augmentation and simultaneous placement of dental implant were included in this study. Subgroup I consisted of patients who had their sinus membrane perforated and repaired during the procedure with resorbable membrane. Subgroup II consisted of patients whose Schneiderian membrane was not perforated during the procedure. The patients were followed between 1 to 4 years after augmentation.

**Results:** All perforations were classified as class II or III. The success rate of the implants in the perforation group was 94.4%, and that for the nonperforation group was 93.9%. The difference between the 2 study groups was statistically not significant. A significant statistical correlation was found between the residual ridge height and the membrane perforation ( $P < .01$ ).

**Conclusions:** Mainly due to technical difficulties, maxillary sinus membrane perforation occurs more frequently with a small height of residual alveolar bone. In this study, no statistical difference was observed in the success rate of the immediate implants placed with sinus bone grafting in patients whose membrane was perforated versus those patients in whom an intact membrane was maintained.

© 2006 American Association of Oral and Maxillofacial Surgeons  
*J Oral Maxillofac Surg* 64:277-282, 2006

Augmentation of the maxillary sinus floor is a well-documented technique and is generally accepted as a pure implantology procedure to facilitate placement of dental implants in the posterior atrophic maxilla. It was first introduced by Tatum<sup>1</sup> and Boyne and James.<sup>2</sup> According to Tatum,<sup>1</sup> The procedure consists of the

preparation of a top hinge door to the lateral wall of the sinus. The door is luxated with the Schneiderian membrane to horizontal position. The space underneath the lifted door is filled with graft material.

The Schneiderian membrane, attached to the bordering bone of the maxillary sinus and characterized by a periosteum overlaid with a thin layer of pseudociliated stratified respiratory epithelium, constitutes an important barrier for the protection and defense of the sinus cavity. Its integrity is essential to maintain the health of normal function of the sinus.

Freeing the membrane during sinus lifting operation is a delicate procedure that is performed by elevation instruments designed by Tatum. However, during sinus lifting, the membrane can be damaged, by overfilling, infection, or perforation.

Overfilling of the maxillary sinus with graft material may cause necrosis of the membrane and loss of the graft into the sinus and also result in sinusitis.<sup>3-5</sup> Galli et al<sup>6</sup> reported that of 14 patients who developed

\*Private Practice, Naharia, Israel; and Senior Surgeon, Department of Oral and Maxillofacial Surgery, Rambam Medical Center, Haifa, Israel.

†Resident, Unit of Periodontology, Rambam Medical Center, Haifa, Israel.

‡Head, Unit of Periodontology, Rambam Medical Center, and Professor, Technion Faculty of Medicine, Haifa, Israel.

§Head, Department of Oral and Maxillofacial Surgery, Rambam Medical Center and Technion Faculty of Medicine, Haifa, Israel.

Address correspondence and reprint requests to Dr Ardekian: Ben Ami St 21, 24319, Akko, Israel; e-mail: ardekian@netvision.net.il

© 2006 American Association of Oral and Maxillofacial Surgeons  
0278-2391/06/6402-0019\$32.00/0  
doi:10.1016/j.joms.2005.10.031

chronic sinusitis after maxillary sinus elevation, more than half received more than the recommended volume (2 to 5 mL) of bone graft.

Although perforation into the maxillary sinus is a cause for concern, the literature provides conflicting and sporadic information concerning the significance of sinus membrane perforation and its influence on the procedure.<sup>6,9</sup>

Perforation of the Schneiderian membrane is a well-documented phenomenon that has been reported since the earliest reports on the procedure. It is most likely to happen at sharp angle and ridge line, septa, and spines.<sup>7</sup> Perforation of the Schneiderian membrane most often occurs when the lateral wall is being fractured, but it can also happen when the membrane is being elevated off the inferior and anterior bony aspect of the sinus and can occur due to irregularities of the sinus floor.<sup>6,8</sup> It has also been suggested by van der Bergh et al<sup>7</sup> that previous sinus surgery (which often results in tissue scar) and absence of alveolar bone are risk factors to perforations of the maxillary sinus, which tend to be large in those cases.

When the perforation is small and located in an area where the elevated mucosa is folded together, it will be healed by itself. If the perforation is large and located in an unfavorable area, the perforation needs to be closed in order to prevent loss of the bone graft.<sup>9</sup>

Perforation of the membrane always threatens the coverage of the graft materials. Many methods have been advocated for treatment of perforation of the Schneiderian membrane during the sinus floor elevation and augmentation. However, there are no guidelines for the treatment of these complications.

In addition, no studies have reported the influence of this perforation on the incidence of complications and the success rate of this procedure.

Therefore, the purpose of this retrospective clinical study was to evaluate the significance of the sinus membrane perforations on the incidence, complications, and success rate of this procedure.

## Patients and Methods

The study population consisted of patients who received sinus floor augmentation and simultaneous placement of dental implant. The study group was divided into 2 subgroups: subgroup I consisted of patients whose sinus membrane was perforated and obliterated during the procedure with resorbable membrane. Subgroup II consisted of patients whose Schneiderian membrane was not perforated during the procedure.

The patients were followed for 1 to 4 years after augmentation. The frequency of complications in

terms of maxillary sinusitis, fistula formation, and pain over the vestibule and the cumulative success rate of the implants were analyzed.

The surgical technique for sinus elevation and augmentation consisted of the technique described by Tatum.<sup>2</sup> A crestal incision was made, and a full-thickness mucoperiosteal flap was elevated. Autogenous bone was grafted by scraping the alveolar crest posteriorly and the zygomatic arch.

According to the computed tomography scan of the patient and the anatomical landmarks, a door (10 to 15 mm × 10 mm) in the lateral wall was prepared. The Schneiderian membrane was freed and carefully separated from the lateral wall of the sinus using blunt instruments. After separation of the Schneiderian membrane, a mix of Bio-Oss (Geistlich, Lucerne, Switzerland) (2 gm) and autogenous bone was applied. Collagenous membrane was placed above the door. A primary closure of the flap wound was achieved using simple silk (4.0) sutures. Postoperative antibiotic (amoxicillin 1.5 gm for 10 days) and mouthwash (chlorhexidine digluconate 0.2% for 6 weeks) were administered. In case of perforation of the Schneiderian membrane, a resorbable collagen membrane (Bio-Mend or Bio-Gide; Geistlich) was inserted and obliterated the perforation. The space underneath the elevated door and the Schneiderian membrane or the collagen membrane was filled with graft material (autogenous bone and Bio-Oss) (Figs 1-3).

The implants (screw type; Medical Implant Systems, Shlomi, Israel) were inserted simultaneously (Fig 4). Perforations were classified according to Valassis and Fugazzotto.<sup>8</sup> This classification (classes I to V) is based on both position and extent. Class I and class II perforations are most easily repaired, while class IV is the most difficult.

### CLASS I

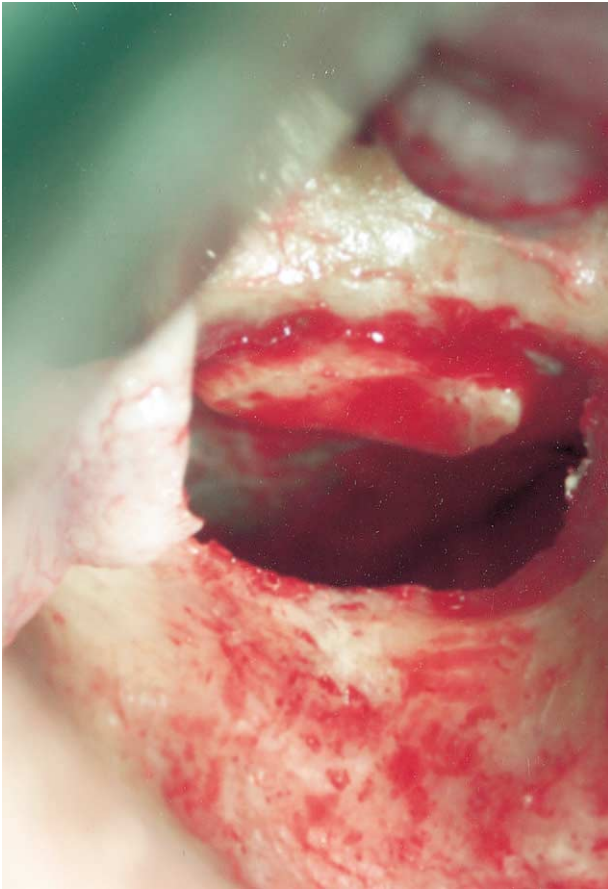
Perforation is adjacent to the osteotomy site. Class I perforations are often "sealed off" as a result of the membrane folding upon itself following completion of elevation. Treatment should be considered when the perforation is still evident after membrane reflection.

### CLASS II

A class II perforation is located in the mid superior aspect of the osteotomy, extending mesiodistally for two thirds of the dimension of total osteotomy site. A class II perforation occurs most frequently when infraction design of the osteotomy is employed. Repair and treatment are similar to those for class I.

### CLASS III

A class III perforation is located at the inferior border of the osteotomy at its mesial or distal sixth.



**FIGURE 1.** Elevated door on the lateral wall of the maxillary sinus. Ardekian et al. *Sinus Membrane Perforation During Augmentation*. *J Oral Maxillofac Surg* 2006.

This is the most common perforation and is almost always the result of inadequacy of osteotomy or improper execution of membrane reflection. Completion of membrane refraction rarely results in covering a class III perforation and treatment is needed.

#### CLASS IV

A class IV perforation is located in the central two thirds of the inferior border of the osteotomy site. Such a perforation is relatively rare and is almost always caused by lack of care when preparing the osteotomy site and represents a considerable clinical challenge.

#### CLASS V

A class V perforation is a preexisting area of exposure of the sinus membrane, due to a combination of extensive antral pneumatization and severe ridge resorption.

#### STATISTICAL ANALYSIS

Descriptive statistics was used to define the various groups. Differences in clinical and radiograph mea-

surements between the groups were evaluated using Student's *t* test for paired observations. The correlations between patient characteristics and membrane perforation were analyzed using Pearson's correlation coefficient test. A 5% significance cutoff was used.

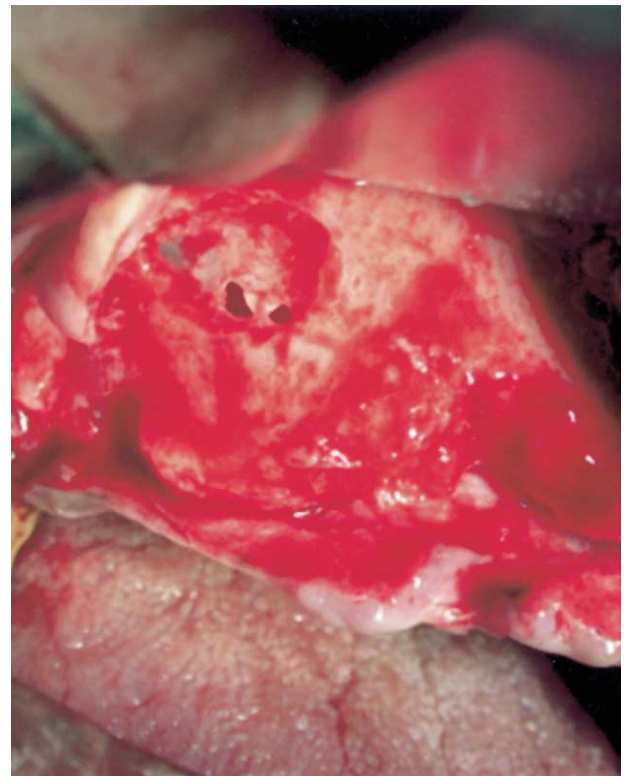## Results

Between the years 1997 and 2003, a total of 110 maxillary sinus augmentations and simultaneous placement of dental implants were performed.

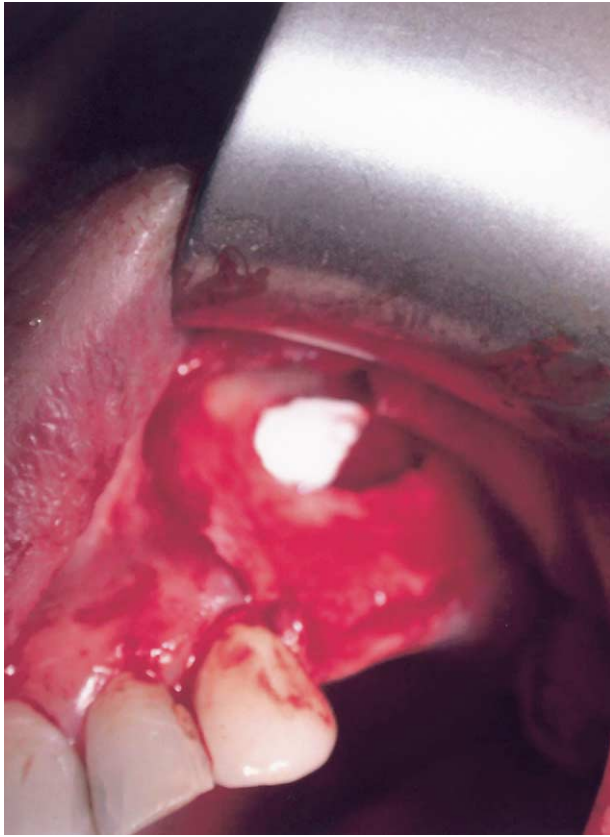
In 35 patients, perforations of the sinus membrane were observed during the procedure: these patients constituted the experimental group. An additional 35 patients without sinus membrane perforations, matched by age and gender, were selected as a control group.

All perforations were classified as class II or III according to the Valassis and Fugazzotto<sup>8</sup> classification. All perforations were <10 mm. Perforations were obliterated using resorbable collagen membrane.

In regard to gender distribution, 42 patients (60%) were females and 28 (40%) were males, and 22 patients (31%) were smokers and 48 (69%) were non-smokers.



**FIGURE 2.** Perforation of the Schneiderian membrane. Ardekian et al. *Sinus Membrane Perforation During Augmentation*. *J Oral Maxillofac Surg* 2006.



**FIGURE 3.** A resorbable collagen membrane (Bio-Gide) was inserted and obliterated the perforation of the sinus membrane.

*Ardekian et al. Sinus Membrane Perforation During Augmentation. J Oral Maxillofac Surg 2006.*

Two hundred twenty-one implants (MIS, Shlomi, Israel) were inserted in 70 patients. Implant lengths were between 13 and 16 mm, and their diameters were between 3.75 and 4.7 mm.

In residual ridge of 3 mm, perforation of the sinus membrane occurred in 85% of cases, while in residual ridge of 6 mm, perforation of the sinus membrane was observed in 25% of cases.

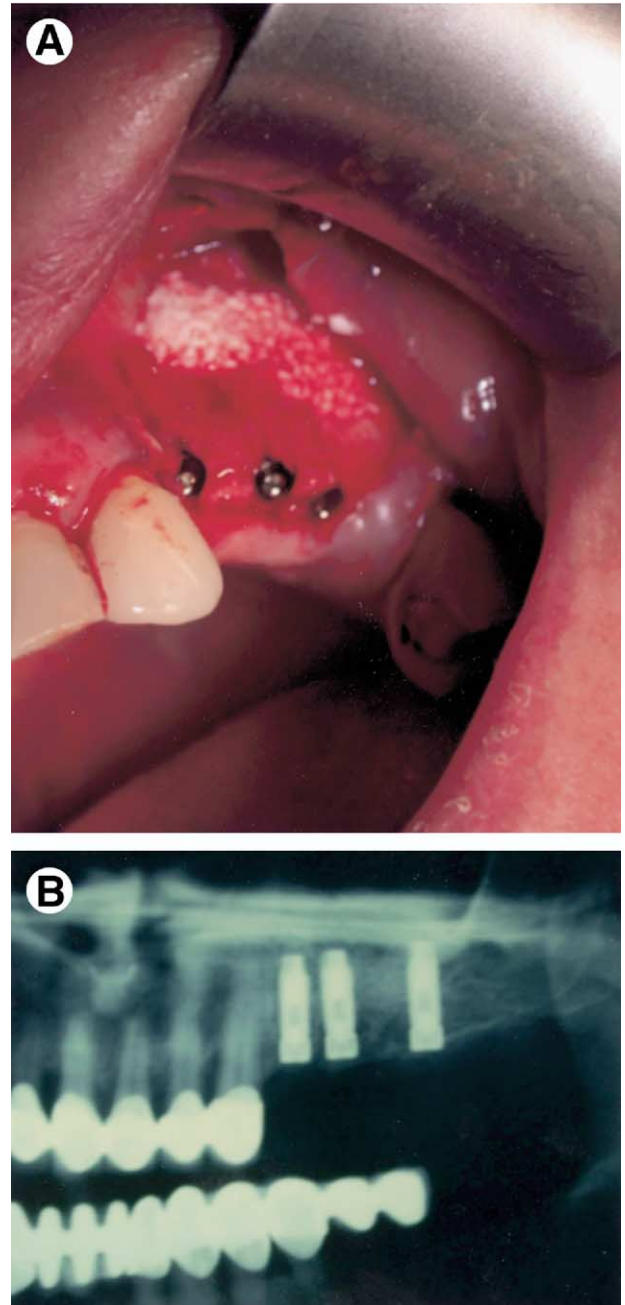
The success rate of the implants 4 years after implantation in the augmented sinus was 94%. When we analyzed our results according to the study groups, we observed that the success rate of the implants in the perforation group was 94.4% and that for the nonperforation group was 93.9%. The difference between the 2 study groups was statistically not significant. We observed one case of acute sinusitis with loss of implant (Fig 5), and one case of oroantral fistula.

A significant statistical correlation was found between membrane perforation and the residual ridge height ( $P < .01$ ) and between smokers and nonsmokers ( $P < .01$ ). No statistical correlation was found between membrane perforation and implant success and failure ( $P > .01$ ).

## Discussion

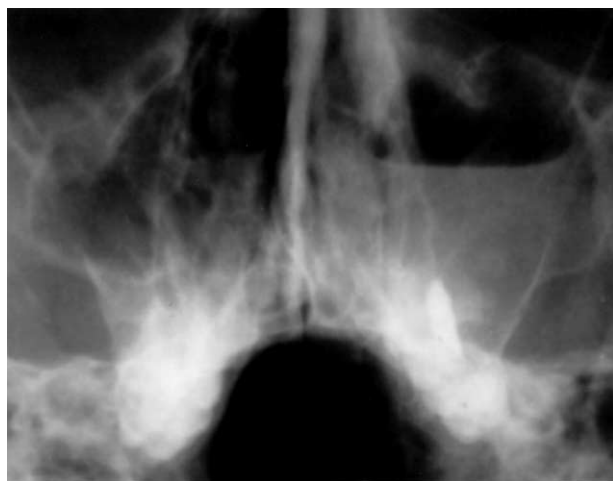The morbidity and complication rate of maxillary sinus augmentation reported in the literature is very low. Among them are perforation of the Schneiderian membrane, chronic or acute sinusitis, cyst, mucocele, disturbed wound healing, hematoma formation, and sequestrum of bone.

Maxillary sinus membrane perforation is the most common complication that occurred with sinus aug-



**FIGURE 4.** The implants (MIS, screw type) were inserted simultaneously with the bone graft. A, Clinical view. B, Radiographic.

*Ardekian et al. Sinus Membrane Perforation During Augmentation. J Oral Maxillofac Surg 2006.*



**FIGURE 5.** Waters view shows opacity of the flow level of the maxillary sinus.

*Ardekian et al. Sinus Membrane Perforation During Augmentation. J Oral Maxillofac Surg 2006.*

mentation; its prevalence is between 20% and 60%. Pikos<sup>9</sup> reported that perforation of the Schneiderian membrane is the most common complication that occurs during the sinus elevation augmentation. He advocates the use of collagen membrane to close small tears (5 to 10 mm) in the Schneiderian membrane and a cross-linked type I collagen membrane for predictable repair of large perforations (>10 mm).

Reiser et al<sup>10</sup> compared the membrane perforation following sinus elevation with crestal osteome and the buccal approach in vitro. Six perforations were recorded, at frequency of 24%. The perforations were associated mainly with the presence of antral septa or the collateral wall of the nose. They classified the perforations according to their severity. Small perforations ( $\leq 2$  mm), lateral or apical, in which the resulting elevated dome-shaped membrane retains its shape once the implant placed, are considered to have a good prognosis. The prognosis of perforation of 2 mm or larger, resulting in an exposed implant to the sinus as well as loss of space and dome shape, is difficult to predict.

Branermark et al<sup>11</sup> reported on implants penetrating the maxillary sinus and the nasal cavity without grafting. The complication rate was not higher than without penetrating implants, and the success rates were comparable. In the study on the morbidity and complication of bone grafting of the floor of the maxillary sinus, Raghoebar et al<sup>12</sup> retrospectively evaluated 75 patients. Perforation of the sinus membrane occurred in 45 patients (60%), but this did not predispose them to the development of sinusitis. Loss of bone particles and sequesteres were observed in only one patient. Similar results—perforation without further complication—have been reported by Jensen et

al,<sup>13</sup> showing complete and spontaneous regeneration after a small perforation.

Aimetti et al<sup>14</sup> evaluated the effect of macrolaceration and microlaceration of the sinus membrane as determined by endoscopy. In the patient who underwent microlaceration of the mucosa during the sinus lifting, the situation was compatible with the healthy condition when evaluated endoscopically. In cases with macrolaceration, the endoscopic picture was typically of sinusitis, even where clinical signs were not evident.

In our study, one patient developed chronic sinusitis and one developed oroantral fistula. These results were similar to those of Skoglund et al,<sup>15</sup> who reported 85 cases of perforations to the maxillary sinus closed within 48 hours. One patient developed an oroantral fistula and sinusitis and an additional 3 patients developed sinusitis. It is important to notice that all cases were treated with the Rehrmann flap procedure or primary suture and in none of them were the implants simultaneously placed. Despite the anatomic proximity of the maxillary to the area in which the procedure took place, the incidence of sinus-related complication is low. Zinner and Small,<sup>16</sup> Raghoebar et al,<sup>5</sup> and Jensen and Sindet-Pedersen<sup>17</sup> reported incidences of sinus complication of less than 1% in 100 patients. Smaller series reported that 5 of 48 developed acute sinusitis. It was not clear whether it developed after placing the bone material or inserting the dental implants.

Kasabah et al<sup>18</sup> evaluated 146 sinus lifting in 118 patients. No relationship was observed between the perforation and the presence of sinus septa, smoking, radiographic thickening, and cystlike lesion in the maxillary sinus and previous sinus allergy. Despite the high prevalence of the perforation of the mucosa (56.6%), no signs of bone graft infection or maxillary sinusitis were noted.

Large perforation represented in the literature an absolute contraindication to continuation of the surgery, especially if the graft material is in granules or chips. The presence of foreign bodies that are free to move inside in the sinus appears to create the situation for initial pathologies of the mucosa.

Misch<sup>19</sup> discussed the risk of infection from maxillary sinus lifting surgery. According to his article, augmentation of maxillary sinus with normal flora should be considered as a clean uncontaminated procedure with low risk of infection of the implant and/or the grafting materials.

In a study that evaluated changes in Schneiderian membrane after maxillary sinus augmentation, Bravetti et al<sup>20</sup> stated that in cases of elevation of the sinus mucosa and insertion of bone graft or any other graft material, the Schneiderian membrane might be

distributed and the graft material can be a source of chronic infection and sinusitis.

The occurrence of iatrogenic sinus membrane perforations during surgery does not seem to be related to sinusitis in healthy people. Large perforations of the maxillary sinus membrane might result in a discharge of bony fragments into the maxillary sinus and thus cause sinusitis.

Peleg et al<sup>21</sup> described one-stage dental implant placement associated with augmentation of the sinus floor. In those 20 patients, graft condensation did not result in perforation of the sinus membrane or in clinically evident complications of the sinuses. Our study population consisted of patients who received sinus floor augmentation and simultaneous placement of dental implant. We found that in residual ridge of 3 mm, perforation of the sinus membrane occurred in 85% of cases, while in residual ridge of 6 mm, perforation of the sinus membrane was observed in 25% of cases. A significant statistical correlation was found between membrane perforation and the residual ridge height ( $P < .01$ ). Van der Bergh et al<sup>7</sup> regarded absence of alveolar bone as one of the risk factors for maxillary sinus perforation. Here we found that when we have small residual alveolar bone height, it is more likely to result in maxillary sinus membrane perforation. This can be explained mainly due to the technical difficulties, to the large area of the membrane to be freed from the lateral wall, and to the decrease in primary stability of the inserted implants.

## References

1. Tatum OH: Maxillary and sinus implant reconstruction. *Dent Clin North Am* 30:207, 1986
2. Boyne P, James RA: Grafting of the maxillary sinus floor with autogenous marrow and bone. *J Oral Maxillofac Surg* 17:113, 1980
3. Tidwell JK, Biljdrop PJ, Stoelinga PJW, et al: Composite grafting of the maxillary sinus for placement of endosteal implants. A preliminary report of 48 patients. *Int J Maxillofac Surg* 55:936, 1992
4. Timmenga NM, Raghoobar GM, Beoring G, et al: Maxillary sinus function after sinus lifts for the insertion of dental implants. *J Oral Maxillofac Surg* 56:1158, 1997
5. Raghoobar GM, Vissink A, Reintsma H, et al: Bone grafting of the floor of the maxillary sinus for the placement of endosseous implants. *Br J Oral Maxillofac Surg* 35:119, 1997
6. Galli SKD, Lebowitz RA, Giacchi RJ, et al: Chronic sinusitis complicating sinus lift surgery. *Am J Rhinol* 15:181, 2001
7. van den Bergh JPA, ten Bruggenkate CM, Disch FJM, et al: Anatomical aspects of sinus floor elevation. *Clin Oral Implant Res* 256, 2000
8. Valassis JM, Fugazzotto PA: A classification system for sinus membrane perforations during augmentation with option to repair. *J Periodontol* 70:692, 1999
9. Pikos MA: Maxillary sinus membrane repair: Report of a technique for large perforations. *Implant Dent* 8:29, 1999
10. Reiser GM, Rabinovitz Z, Bruno J, et al: Evaluation of maxillary sinus membrane response following elevation with the crestal osteome technique in human cadavers. *Int J Maxillofac Implants* 16:833, 1999
11. Brenemark AM, Adell R, Albrektsson T, et al: An experimental and clinical study of osseointegrated implants penetrating the nasal cavity and maxillary sinus. *J Oral Maxillofac Surg* 42:497, 1984
12. Raghoobar GM, Batenburg RH, Timmenga NM, et al: Morbidity and complication of bone grafting of the floor of the maxillary sinus for placement of endosseous implants. *Mund Kiefer Gsrchtschir* 3:65, 1999
13. Jensen J, Sindet-Pedersen S, Oliver AJ: Varying treatment strategies for reconstruction of maxillary atrophy with implants: Results in 98 patients. *J Oral Maxillofac Surg* 52:210, 1994
14. Aimetti M, Romagnoli R, Ricci G, et al: Maxillary sinus elevation: The effect of macrolaceration and macrolaceration of the sinus membrane as determined by endoscopy. *Int J Periodont Restor Dent* 21:581, 2001
15. Skoglund LA, Pedersen SS, Holst E: Surgical management of 85 perforations to the sinus. *Int J Maxillofac Surg* 12:1, 1983
16. Zinner ID, Small SA: Sinus-lift graft: Using the maxillary sinuses to support implants. *J Am Dent Assoc* 27:51, 1996
17. Jensen J, Sindet-Pedersen S: Autogenous mandibular bone grafts and osseointegrated implants for reconstruction of the severely atrophied maxilla: A preliminary report. *J Oral Maxillofac Surg* 49:1277, 1991
18. Kasabah S, Krug J, Simunek A, et al: Can we predict maxillary sinus perforation? *Acta Med* 46:19, 2003
19. Misch CE: The pharmacologic management of maxillary sinus elevation surgery. *J Oral Implants* 18:15, 1992
20. Bravetti P, Membre H, Marchal L, et al: Histologic changes in the sinus membrane after maxillary sinus augmentation in goats. *Oral Maxillofac Surg* 56:1170, 1998
21. Peleg M, Mazor Z, Chaushu G, et al.: Sinus floor augmentation with simultaneous implant placement in the severely atrophic maxilla. *J Periodontol* 69:1397, 1998